

# Resolution of a left sided 5<sup>th</sup> phalangeal 2<sup>nd</sup> inter-phalangeal joint stenosing tenosynovitis (trigger finger) in a 2½ year-old female: Case report

Martin G. Rosen and Charles Blum

**Abstract: Introduction:** While a condition such as stenosing tenosynovitis (trigger finger) is not usually considered neurological or musculoskeletal in nature it is relevant that in this case conventional chiropractic care applied mainly at the spinal level appeared to facilitate a complete resolution of the patient's trigger finger.

**Case:** A 2½ year old female was seen for her first chiropractic evaluation on June 22, 2012 presenting with stenosing tenosynovitis (trigger finger), unresponsive to prior care (e.g., medication, injections, and physical therapy) and hoping for an alternative to surgery.

**Methods:** Based upon the examination findings and previous treatment history, chiropractic adjustments using sacro occipital technique (SOT) protocols were directed to C4, T6, left scapula, left 1<sup>st</sup> rib head and left wrist.

**Results:** After seven chiropractic adjustments this 2½ year-old child's trigger finger was 80-90% resolved. At 6-month follow-up the mother indicated the child's trigger finger had continued to improve following care and was completely resolved.

**Conclusion:** Because allopathic intervention for this condition appears to have questionable outcomes and risks, chiropractic care may be a viable and safe initial step to take before exploring the more invasive and costly options.

**Indexing Terms:** Chiropractic, stenosing tenosynovitis, sacro-occipital technique, paediatric.

## Introduction

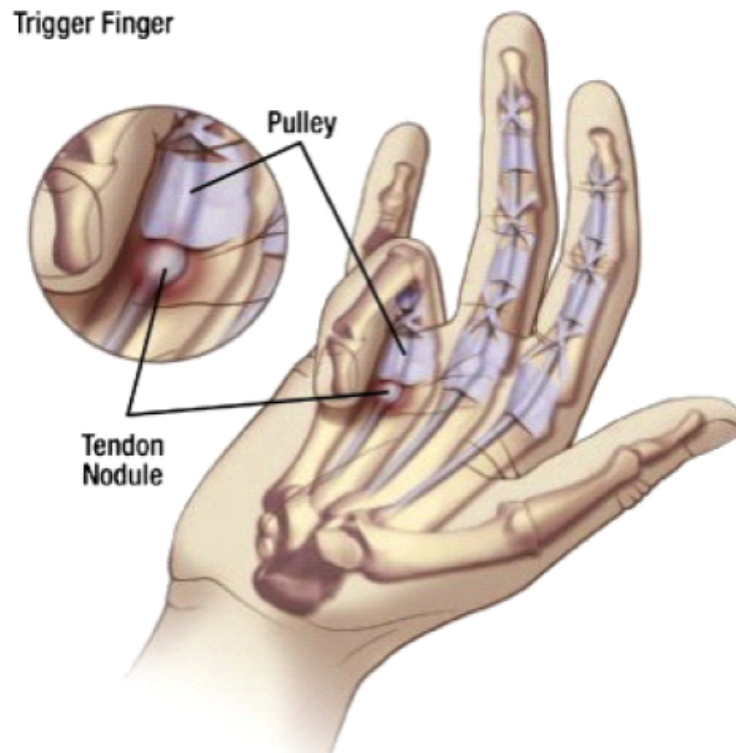
The purpose of this paper is to propose that conventional chiropractic care including Sacro Occipital Technique (SOT) protocols utilized for evaluation and adjusting of subluxation patterns may have a global effect on health. While a condition such as stenosing tenosynovitis (trigger finger) is not usually considered neurological or musculoskeletal in nature it is relevant that in this case conventional chiropractic care applied mainly at the spinal level appeared to facilitate a complete resolution of the patient's trigger finger.

The standard medical approach to treat tenosynovitis is multi-faceted dependent on the severity of the symptoms and duration. Trigger finger treatment varies depending on its severity and duration. For mild or infrequent symptoms, a standard approach is wearing a splint to keep the affected finger in an extended position for up to six weeks. The splint helps to

*... SOT is an appropriate technique for paediatric patients and this case demonstrates that spinal care may be associated with the resolution of distal presentations like tenosynovitis'*



rest the joint and prevents the patient from curling their fingers into a fist while sleeping. Finger exercises may also be considered and they involve gentle exercises with the affected finger to help maintain finger mobility. Avoiding repetitive gripping is also performed for at least three to four weeks. This includes avoiding activities that require repetitive gripping, repeated grasping or the prolonged use of vibrating hand-held machinery. (1)



For more-serious symptoms other approaches tend to include nonsteroidal anti-inflammatory drugs (NSAID's). NSAIDs such as ibuprofen (Advil, Motrin, others) are believed to help relieve the swelling constricting the tendon sheath and trapping the tendon. These medications can also relieve the pain associated with trigger finger. When the tenosynovitis is not responsive to NSAIDs then sometimes an injection of a steroid medication, such as a glucocorticoid, near or into the tendon sheath may be used to reduce inflammation of the sheath. This treatment is most effective if given soon after signs and symptoms begin and the injections can be repeated if necessary.

Steroid injections may not be as effective in people with other medical conditions, such as rheumatoid arthritis or diabetes. (2) If steroid medication is not successful then a needle injection may be necessary and is called a percutaneous trigger finger release. With this procedure, performed with local anesthesia, the doctor uses a needle to release the trigger finger. (3) This procedure is most effective for the index, middle and ring fingers. When conservative methods do not help surgery may indicated and although less common than other treatments, surgical release of the tendon may be necessary for unresponsive troublesome locking. (4, 5).

Treatment of children with tenosynovitis is not prevalent in the literature with one study discussing reserving surgical release for children with digits locked in flexion (6) and another advising caution in the treatment of children with concurrent hand infections (pyogenic stenosing tenosynovitis). (7)

Typically chiropractic management of trigger finger often involves myofascial release of the flexor tendons, physical therapeutic interventions (massage, ultrasound, ice, etc,) rehabilitative exercises, ergonomic modifications, splinting, and rest from aggravating activities. (8, 9) Also in some instances acupuncture may offer some positive results in treating this condition. (10)

### Methods/Interventions

A 2½ year old female was seen for her first chiropractic evaluation on June 22, 2012 presenting with stenosing tenosynovitis (trigger finger). Upon her evaluation it was noted that she was unable to straighten her left little finger at the second phalangeal joint without the assistance of the other hand. If she attempted to flex her finger her finger would 'lock.' Her previous treatment included; NSAID's, restriction of movement, and joint mobilization. The patient's condition was not responsive to these interventions so surgery to release the tendon was recommended.

The chiropractic evaluation also revealed subluxations of C4-C5 and T12-L1 as well as a laterally deviated left scapula and 1<sup>st</sup> costovertebral junction. Palpatory swelling and decreased range of motion were discovered at the ulnar aspect of the left wrist. The patient was placed on a program of two chiropractic adjustments per week, for three weeks starting on June 26, 2012.

Based upon the examination findings and previous treatment history, chiropractic adjustments using SOT protocols were directed to C4, T6, left scapula, left 1<sup>st</sup> rib head and left wrist. This adjustment/subluxation pattern was addressed for two visits before a change in the pattern occurred. On July 3, 2012 adjustments were made to C6, C2 and her left wrist and on July 10, 2012 adjustments to C6, T3 and her left wrist were performed.

Following the July 10<sup>th</sup> office visit her mother reported that the patient's finger was not '*getting stuck every time the child flexed it*' and that her daughter '*was not playing with the finger as much*'. Over the next two visits the child's general subluxation/distortion pattern continued to reduce and by her last visit on July 24, 2012 adjustments were made to C6 and T3 only. When further care was suggested to address the child's remaining subluxation patterns the mother decided to discontinue active care since the condition – stenosing tenosynovitis – had resolved significantly.

### Results

After seven chiropractic adjustments this 2½ year-old child's trigger finger was 80 - 90% resolved. At that point in time the mother decided to discontinue care until such time as she felt further chiropractic adjustments were necessary.

Upon follow up we contacted the mother by email in January 2013 to see how he child was doing. She reported that the trigger finger completely resolved a few weeks after we last saw her and has not returned. The mother was profoundly grateful for the care delivered to her child and particularly that that her child did not have to undergo anaesthesia and surgical intervention.

### Discussion

A search of PubMed, MANTIS, and ChiroIndex.com did not find any chiropractic studies relating to pediatric care of tenosynovitis. There were two studies discussed in the literature of stenosing tenosynovitis in the adult population treated with chiropractic care and ancillary procedures. (8, 9)

While as stated earlier direct clinical evidence is not conclusive from one case study it is important to note that in this particular case the patient made no other alterations in her lifestyle or clinical situation other than she discontinued the NSAID's and exercises that were previously suggested. The only other variable appeared to be addition of chiropractic care

## Figures

### The Amsterdam Severity Scale in Stenosing Tenosynovitis (ASSIST)

#### Grading of Stenosing Tenosynovitis

Grade 0	No impairment
Grade 1	Palpable nodule or crepitation, with normal active range of motion (AROM)
Grade 2	A perceptible click or a reduced tempo of active finger flexion in combination with a full (AROM) determined by the maximum passive range of motion (PROM).
Grade 3	Restriction in (AROM) by a tendon obstruction under the pulley's or within the tendon sheath

NOTE: The ASSIST can be used to reliably assess the severity of stenosing tenosynovitis in both nodular and diffuse forms, but it does not differentiate between these two forms. (15)

## QuickDASH-9

**INSTRUCTIONS:** This questionnaire asks about your symptoms as well as your ability to perform certain activities. Please answer *every question*, based on your condition in the last week, by circling the appropriate number. If you did not have the opportunity to perform an activity in the past week, please make your *best estimate* of which response would be the most accurate. It doesn't matter which hand or arm you use to perform the activity; please answer based on your ability regardless of how you perform the task.

Rate your ability to do the following activities in the last week by circling the number below the appropriate response.

	NO DIFFICULTY	MILD DIFFICULTY	MODERATE DIFFICULTY	SEVERE DIFFICULTY	UNABLE
1. Open a tight or new jar.	0	1	2	3	4
2. Do heavy household chores (e.g., wash walls, floors).	0	1	2	3	4
3. Carry a shopping bag or briefcase.	0	1	2	3	4
4. Wash your back.	0	1	2	3	4
5. Use a knife to cut food.	0	1	2	3	4
6. Recreational activities in which you take some force or impact through your arm, shoulder or hand (e.g., golf, hammering, tennis, etc.).	0	1	2	3	4

	NOT AT ALL	SLIGHTLY	MODERATELY	QUITE EXTREMELY A BIT	
7. During the past week, to what extent has your arm, shoulder or hand problem interfered with your normal social activities with family, friends, neighbours or groups?	0	1	2	3	4

	NOT AT ALL	SLIGHTLY LIMITED	MODERATELY LIMITED	VERY LIMITED	UNABLE
8. During the past week, were you limited in your work or other regular daily activities as a result of your arm, shoulder or hand problem?	0	1	2	3	

	NONE	MILD	MODERATE	SEVERE	EXTREME
9. Arm, shoulder or hand pain.	0	1	2	3	4

A QuickDASH-9 score may not be calculated if there is greater than 1 missing item.

QuickDASH-9 SCORE =  $\frac{[(\text{sum}) \times 1.1]}{5/2}$ , a missing response is added as the average of the remaining.

A correlation was noted between the reduction of the patient's subluxation complex and her resolution of her trigger finger. This is interesting since it appeared that a relationship between general body health, spinal balance with symmetry in structure and function appeared to have both a general and specific effect on the patient's symptom presentation. Theoretically this could have been because with subluxation reduction there was improved neuromuscular function (11, 12) leading to reduced local inflammation, balanced trophic function (13) to her fingers, and facilitating neurodynamics in finger use. It is also possible that subluxation reduction may have a positive effect on kinesiological, biomechanical and histological imbalances at end organ sites. (14)

There are some outcome assessment forms which can be used in assessing and treating stenosing tenosynovitis with one specific for this condition, '*The Amsterdam Severity Scale in Stenosing Tenosynovitis (ASSIST)*' (15) and another more general to assess upper extremity disability, shortened disabilities of the '*Arm, Shoulder, and Hand Questionnaire*' (Quick DASH). (16, see figures)

With any case report it is difficult to generalize the findings from this study due to lack of multiple subjects with a control or sham intervention group to rule out effects such as ideomotor, placebo, regression to the mean, or that the outcome may have been coincidental and not causal. However the temporal nature of the patient's response to care along with the unresponsiveness to prior interventions makes the results from this study compelling.

### Conclusion

Conventional chiropractic care inclusive of SOT protocols in this case offered less risk to the patient than both the previous treatment modalities and suggested interventions including: medications, steroid injections, or surgery and appeared to attain significant benefit and a positive outcome in this case.

Based on the low-risk aspects of the care rendered in this case further study into the efficacy of chiropractic care in the treatment of stenosing tenosynovitis and the etiology of the corrective process would be of value.

At this point in time because medical intervention in this condition appears to be limited and fraught with questionable outcomes and risks, chiropractic care may be a viable and safe initial step to take before exploring the more invasive and costly options. Further study is also indicated exploring the effects of improved structural and functional spinal symmetry and their relationship to specific presentations such as stenosing tenosynovitis.



Charles L Blum

DC

[drclblum@aol.com](mailto:drclblum@aol.com)

Martin G. Rosen

DC

Private Practice

Informed consent to chiropractic care is held by the practitioner.

**Cite:** Rosen MG, Blum C. Resolution of a left sided 5th phalangeal 2nd inter-phalangeal joint stenosing tenosynovitis (trigger finger) in a 2½ year-old female. [Case Report]. Asia-Pac Chiropr J. 2021;2.1:Online only. URL [www.apcj.net/papers-issue-2-1/#Rosentenosynovitis](http://www.apcj.net/papers-issue-2-1/#Rosentenosynovitis)

## References

1. Vuillemin V, Guerini H, Bard H, Morvan G. Stenosing tenosynovitis. J Ultrasound. 2012 Feb;15(1):20-8.
2. Ursum J, Horsten NC, Hoeksma AF, Dijkmans BA, Knol DL, van Schaardenburg D, Dekker J, Roorda LD. Predictors of stenosing tenosynovitis in the hand and hand-related activity limitations in patients with rheumatoid arthritis. Arch Phys Med Rehabil. 2011 Jan;92(1):96-100.
3. Murphy AD, Lloyd-Hughes H, Ahmed J. Complex regional pain syndrome (Type 1) following steroid injection for stenosing tenosynovitis. J Plast Reconstr Aesthet Surg. 2010 Oct;63(10):e740-1.
4. Scheller A, Schuh R, Hönle W, Schuh A. Long-term results of surgical release of de Quervain's stenosing tenosynovitis. Int Orthop. 2009 Oct;33(5):1301-3.
5. Mayo Clinic Staff. Trigger finger: Treatment and drugs. Oct. 25, 2011. [<http://www.mayoclinic.com/health/trigger-finger/DS00155/DSECTION=treatments-and-drugs>] Last accessed April 20, 2013.
6. Kraemer BA, Young VL, Arfken C. Stenosing flexor tenosynovitis. South Med J. 1990 Jul;83(7):806-11.
7. Luria S, Haze A. Pyogenic flexor tenosynovitis in children. Pediatr Emerg Care. 2011 Aug;27(8):740-1.
8. Papa JA. Conservative management of De Quervain's stenosing tenosynovitis: A case report. J Can Chiropr Assoc. 2012 Jun;56(2):112-120.
9. Howell ER. Conservative care of De Quervain's tenosynovitis/tendinopathy in a warehouse worker and recreational cyclist: A case report. J Can Chiropr Assoc. 2012 Jun;56(2):121-127.
10. Schulman RS, Levchenko AL, Lombardo SRL. Trigger finger in a male with diabetes successfully treated with acupuncture and osteopathic manipulative treatment. Medical Acupuncture. 2013 Feb; 25(1):74 – 77.
11. Haavik T H, Holt K, Murphy B. Exploring the neuromodulatory effects of the vertebral subluxation and chiropractic care. Chiropr J Aust. 2010 Mar;40(1):37-44.
12. Bakkum BW, Cramer GD, Henderson CNR, Hong S-P. Does subluxation actually affect the nervous system? Preliminary morphologic evidence that it does. J Chiropr Educ. 2006 Spr;20(1):1-2.
13. Ermachenko BA. [Neurodystrophic lesions of the osteoarticular apparatus and their importance in assessing the trophic function of the spinal cord]. [Article in Russian] Zh Nevropatol Psikhiatr Im S S Korsakova. 1978;78(5):649-54.
14. Association of Chiropractic Colleges. Chiropractic Paradigm: 4.0 The Subluxation. [<https://www.chirocolleges.org/chiropractic-paradigm-scope-practice> Last accessed April 2, 2021.]
15. Peter WF, Steultjens MP, Mesman T, Dekker J, Hoeksma AF. Interobserver reliability of the Amsterdam Severity Scale in Stenosing Tenosynovitis (ASSIST). J Hand Ther. 2009 Oct-Dec;22(4):355-9; quiz 360.
16. Gabel CP, Yelland M, Melloh M, Burkett B. A modified QuickDASH-9 provides a valid outcome instrument for upper limb function. BMC Musculoskelet Disord. 2009 Dec 18;10:161.

## Poster



# Resolution of a left sided 5<sup>th</sup> phalangeal 2<sup>nd</sup> inter-phalangeal joint stenosing tenosynovitis (trigger finger) in a 2 1/2 year-old female: A case report

Martin Rosen DC, Charles Blum DC, & Erin Rosen DC  
Sacro Occipital Technique Organization – USA

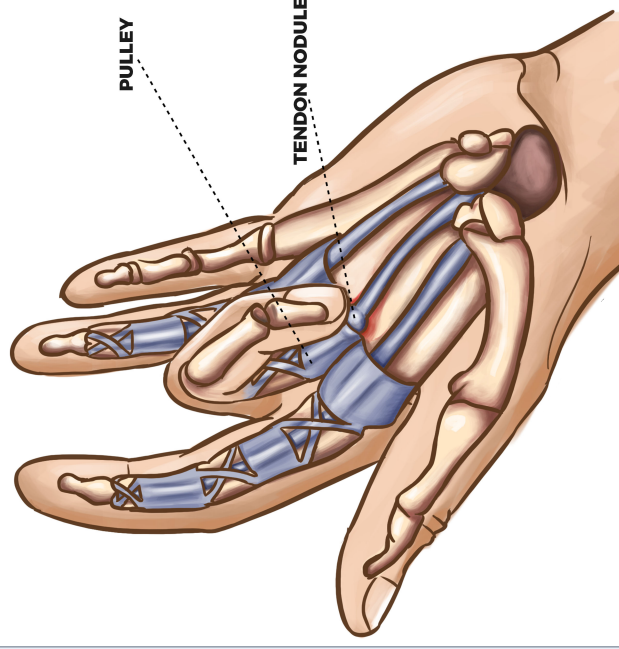
## Objective/Clinical Feature

While a condition such as tenosynovitis (trigger finger) is not usually considered neurological or musculoskeletal in nature it is relevant that in this case standard chiropractic care applied mainly at the spinal level appeared to facilitate a complete resolution of the patient's trigger finger. A 2 1/2 year old female was seen for her first chiropractic evaluation on June 22, 2012 presenting with stenosing tenosynovitis (trigger finger), unresponsive to prior care (e.g., medication, injections, and physical therapy) and parents were hoping for an alternative to surgery.

## Intervention

Based upon the comprehensive, examination findings, chiropractic adjustments using Sacro Occipital Technique® (SOT®) protocols were directed to C4, T6, left scapula, left 1st rib-head and left wrist.

## Results



After seven chiropractic adjustments this 2 1/2 year-old child's trigger finger was 80-90% resolved. At 6-month follow-up the mother indicated the child's trigger finger had continued to improve following care and was completely resolved.

## Discussion

The patient made no other alterations to her lifestyle except discontinuing NSAID's and exercises that were previously suggested. The only variable facilitating the resolution of her condition appeared to be the addition of chiropractic care. To date this is the only case report of chiropractic treatment for "trigger finger" in a pediatric patient.<sup>1,2</sup>

## Conclusion

Because allopathic intervention for this condition appears to have questionable outcomes and risks, chiropractic care may be a viable and safe initial conservative first step to take before exploring the more invasive and costly options.

## References

1. Papa JA. Conservative management of De Quervain's stenosing tenosynovitis: A case report. *J Can Chiropr Assoc.* 2012 Jun;56(2):112-120.
2. Howell ER. Conservative care of De Quervain's tenosynovitis/tendinopathy in a warehouse worker and recreational cyclist: A case report. *J Can Chiropr Assoc.* 2012 Jun;56(2):121-127.