

# Sacro Occipital Technique (SOT) Chiropractic and Nocturnal Enuresis in children: A report of three cases

---

Rosina Walker

---

**Introduction:** Nocturnal Enuresis is when bedwetting continues past an age where the bladder is neurologically and physically developed to be able to hold the urine all night. This case series shares three children with nocturnal enuresis presenting for chiropractic assessment and treatment.

**Methods/Intervention:** The three children in this study had some common physical examination findings such as decreased right psoas and left lower core (*transverse abdominus*) muscle strength, persisting positive Spinal Galant primitive reflex, large right thoracic translations, and sacro occipital technique (SOT). Chiropractic manipulative reflex technique (CMRT) finding of occipital fibre line #2-T11/12 with CMRT kidney reflexes being active and signs of kidney ptosis.

A care plan began with two visits per week for three weeks, to be followed by a reassessment. The three children were each adjusted using SOT techniques including the pre-blocking techniques: Kidney ptosis and psoas correction. Spinal subluxations were monitored and adjusted as indicated. Occipital reflex lines were monitored and T11/12 reflexes were performed until the reflex was no longer active. CMRT reflex kidney technique was performed when indicated.

**Results:** At the three-week re-examination of all three children it was noted that: (i) All muscle tests were now within normal limits, (ii) Posture was significantly improved, (iii) The Spinal Galant primitive reflex was now absent, and (iv) Report of the parent and child indicated that bedwetting had significantly decreased.

**Conclusion:** After their plan of care, including spinal adjustments, plus SOT techniques to balance the viscerosomatic and somatovisceral reflex activity, their nocturnal enuresis markedly reduced. Following a series of adjustments, all muscle tests, and primitive reflexes were within normal limits and their posture had improved.

**Indexing terms:** Enuresis; Bedwetting; Chiropractic; Sacro Occipital Technique; SOT; Chiropractic Manipulative Reflex Technique; CMRT; Occipital Fibres

## Introduction

Nocturnal Enuresis is when bedwetting continues past an age where the bladder is neurologically and physically developed to be able to hold the urine all night. This condition is often differentiated between primary and secondary findings:

- ▶ Primary nocturnal enuresis is bedwetting in a child who has never been consistently dry at night for a period of six months
- ▶ Secondary nocturnal enuresis is bedwetting in a child who has previously

... Common findings are noted among 3 children with enuresis. Low-force SOT techniques resulted in corrected posture and dry nights ...'



had a period of at least six months of dryness. (1)

Bedwetting affects approximately:

- ▶ 15% of 7 year olds (2)
- ▶ 10% of 10 year olds (3, 4)
- ▶ 2% of adolescents (5)
- ▶ 1% of adults (6)

Spontaneous remission occurs in about 15% of affected children each year and nocturnal enuresis is more likely to occur if there is a family history, particularly if both parents have had this disorder. (2, 3) It is thought that fewer than half of parents with a child with nocturnal enuresis consult their doctor about the problem. The exact cause of nocturnal enuresis is unknown and appears to be a neurodevelopmental problem that is probably multifactorial. (7) *'It is essential to demystify the problem and reassure parents by educating them that the episodes are nonvolitional and most children outgrow the problem over time'*. In general *'behavioural interventions are considered first line and are most successful when the child is invested in succeeding.'* (8, 9)

Nocturnal enuresis can be categorised into monosymptomatic (MEN) and non-monosymptomatic (NMEN) forms. MEN occurs without any other symptoms of bladder dysfunction. NMEN is associated with dysfunction of the lower urinary tract with or without daytime incontinence. (10, 11) Most commonly children with MEN will outgrow the condition spontaneously, however *'the psychological effect to the child can be significant and represents the main reason for treatment of these children'*. Consensus panels suggest that children with NMEN often *'should have their underlying voiding or stool problem addressed before initiation of therapy for the nocturnal enuresis.'* (12)

Allopathic care of a child with nocturnal enuresis notes that the most important comorbid conditions to take into account are psychiatric disorders, constipation, urinary tract infections and snoring or sleep apneas. Constipation and daytime incontinence, if present, should be treated. With children with MEN presentations where conservative methods are not effective *'the first-line treatment modalities are Desmopressin or the enuresis alarm. If both these therapies fail alone or in combination, anticholinergic treatment is a possible next step. If the child is unresponsive to initial therapy, antidepressant treatment'* may need to be considered. (13, 14, 15, 16)

Studies into children with nocturnal enuresis are finding that there may be complex interactions relating to this type of presentation. For some children it has been suggested that their condition is influenced by *'disturbances in the circadian rhythm of arginine-vasopressin'*, (17) airway compromise, (18) dental growth and development issues, (19) and sleep disorders (20, 21) There seems to be an interrelationship between children with attention deficit hyperactivity disorder (ADHD) and nocturnal enuresis, since *'enuresis seems to persist for more time in children with ADHD.'* (22)

While children with nocturnal enuresis may 'outgrow' this condition, due to its relationship to their *'self-esteem (sadness, anxiety, social fears, distress)'*, (23) which is significantly greater than children without enuresis, parents often do not want to 'watch and wait.' Since quality of life affects are common for these children it would appear that finding low risk, conservative, interventions should be the initial frontline options in care of children with nocturnal enuresis. (24) While nothing definitive has been found there are a significant number of case studies demonstrating good outcomes for children with nocturnal enuresis responding favourably to chiropractic care interventions. (25, 26, 27, 28, 29, 30, 31, 32, 33, 34, 35, 36, 37, 38, 39, 40, 41, 42, 43, 44, 45) Interestingly a *Cochrane Systematic Review* noted *'spinal manipulation seemed to give better results than sham adjustment ...'* (46)

One technique system within the chiropractic field, sacro occipital technique (SOT) (47, 48, 49) has a method called chiropractic manipulative reflex technique (CMRT), (50, 51) which has shown good outcomes treating children with nocturnal enuresis. (52) Postles and Haavik discussed that a '*child received spinal and cranial adjustments based on Sacro Occipital Technique (SOT) protocol. After 32 weeks of chiropractic care the child no longer had asthma symptoms, bedwetting had ceased and a positive change in other presenting symptoms was noted.*' (53)

It is important that before considering chiropractic care of a child with nocturnal enuresis to rule out:

- ▶ Bladder dysfunction from infection or neurological conditions,
- ▶ Incontinence due to anatomical abnormalities, and
- ▶ Polyuria secondary to *diabetes mellitus, diabetes insipidus*, excessive fluid or diuretic intake, or drugs. (1)

At a local '*Mums and Babies*' site I was the 'go to' chiropractor for children with bedwetting issues. After taking histories and performing physical examinations on three children presenting with nocturnal enuresis I noticed that they had very similar postural, muscle, neurological, physiological, and SOT findings:

A 7 year old girl was a twin, had had an unusual womb presentation, in her first months of life presented with colic and projectile vomiting, and was medicated until she was 18mo old. Along with nocturnal enuresis she also presented with abdominal pain, bowel issues (alternating constipation and diarrhoea), eczema and a 'lazy' left eye. She was also experiencing emotional distress due to parents going through a divorce.

A 7 year old boy presented with an overactive bladder during the day and nocturnal enuresis. He had seen a paediatrician four years ago as well as an urologist. He had been medicated since he was 4 years old with Oxybutrinin (antispasmodic for bladder) and then one year ago his allopathic general practitioner added Desmopressin (controls increased thirst) and Imipramine (an antidepressant). His kidney and bladder ultrasound assessment was within normal limits.

A 10 year old boy was being woken by his parents twice every night to go to the bathroom. He also presented with frontal and suboccipital headaches once or twice a month. His kidney and bladder ultrasound assessment was within normal limits.

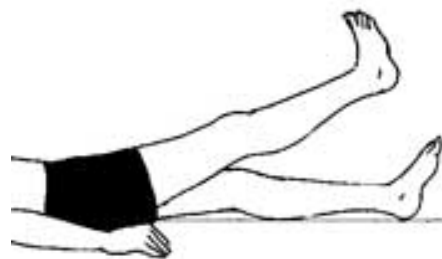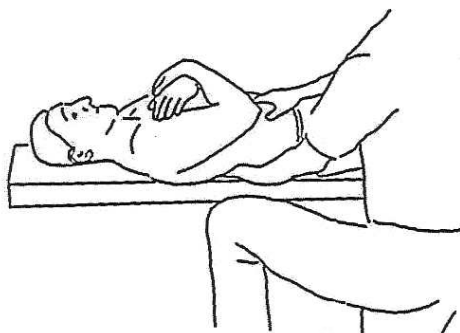
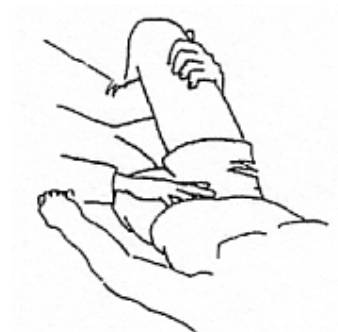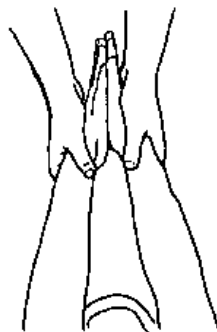
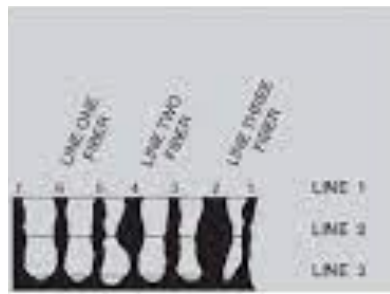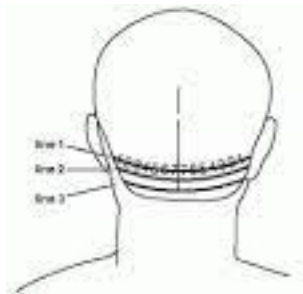
## Treatment

As stated previously these three children had some common physical examination findings:

- Physical exam: Decreased right psoas and left lower core (transverse abdominus) muscle strength relative to the contralateral side with weakness at 4/5.
- Neurological: All deep tendon reflexes were within normal limits.
- Primitive Reflexes: All three children had signs of a persisting positive *Spinal Galant* reflex. (54)
- Posture: Large right thoracic translations
- Spinal Subluxations: C2, T11/T12, L3, L4, and sacrum.
- SOT/CMRT Findings: Occipital Fibre Line #2-T11/12, CMRT kidney reflexes were active with findings of kidney ptosis.

A care plan began with two visits per week for three weeks, to be followed by a reassessment. The three children were all adjusted using SOT Techniques including the pre-blocking techniques: Kidney ptosis and psoas correction. Spinal subluxations were monitored and adjusted as

indicated. Occipital reflex lines were monitored and T11/12 reflexes were performed until the reflex was no longer active. CMRT reflex kidney technique was performed when indicated.



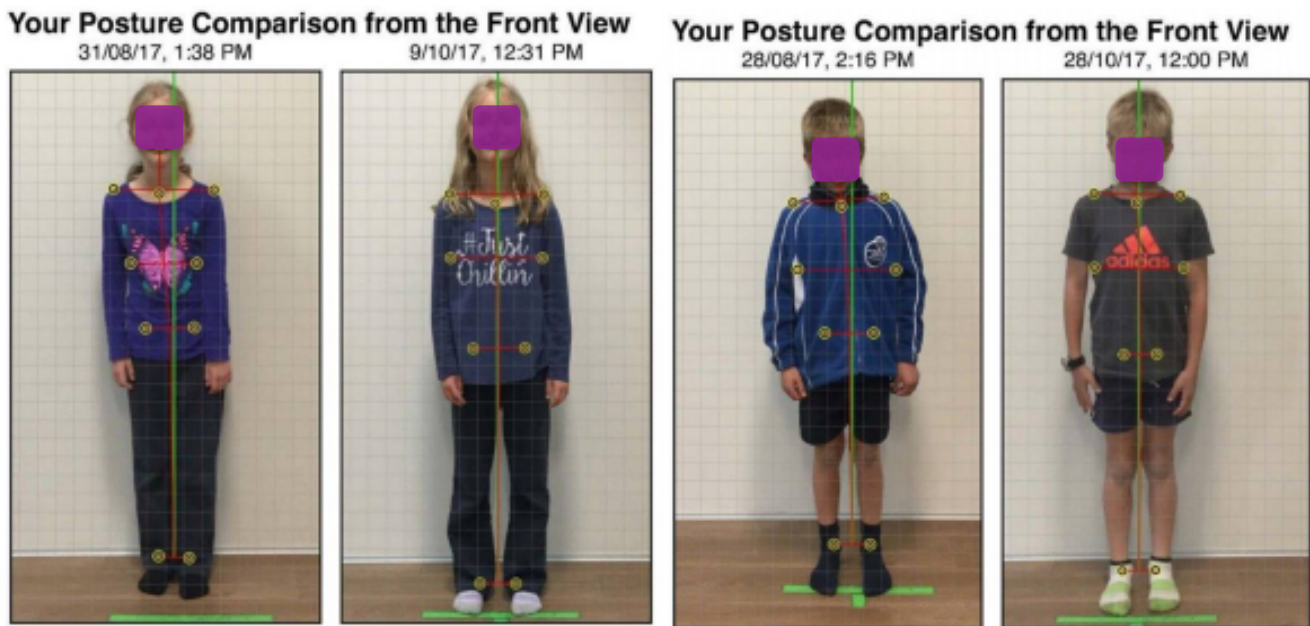
All parents were asked to increase their child's vitamin C intake and cut down the intake of dairy, sugar and wheat. Individually, the children all had their separate care plans with the following elements:

- ▶ Stress management for parent/sibling relationships
- ▶ SOT cranial adjustments, specific to each child's needs
- ▶ Goal to reduce medications.

## Results

At the three-week re-examination of all three children it was noted that:

- ▶ All muscle tests were now within normal limits
- ▶ Posture was significantly improved (see figure)
- ▶ The *Spinal Galant* primitive reflex was now absent
- ▶ Report of the parent and child indicated that bedwetting had significantly decreased.



## Discussion

The postural changes found relate to the tension in the dural system consistent with a SOT Category 1. This includes pelvic rotation, lateral thoracic translation to the opposite side, and contralateral movement of the cervicals. Category 1 involves the central nervous system function, spinal muscles such as erector spinae and organ function. Category 1's relationship to organ function can affect the autonomic nervous system, causing the body when under stress to be in an increased sympathetic state. This increased sympathetic activity can unfavourably affect kidney function and output. (48, 49)

*Chiropractic Manipulative Reflex Technique* (CMRT) is based on the premise that chronic somatovisceral and viscerosomatic aberrant reflexes will adversely affect the function of the nervous system and perturb the vertebral subluxation complex. Because of this, visceral dysfunction may follow, pathological reflexes may be established, and disease may manifest itself in the form of symptoms. CMRT normalises somato-visceral and somato-spinal reflex arcs that can help to prevent the 'repeat adjustment' syndrome. CMRT's focus is to help interrupt chronic pain patterns and correct functional organ disturbances. (51, 55, 56, 57)

The finding that indicated the need for CMRT (viscerosomatic therapy) in these children was a Line 2 Occipital Fibre relating to T11/T12. If a Line 2 fibre stays present (swollen and tender), this indicates that a detrimental viscerosomatic and somatovisceral reflex arc has developed that is beyond the body's natural healing capabilities to repair this subluxation pattern on its own. (58, 59, 60, 61, 62)

The theoretical effects of occipital fibre analysis, treatment, and CMRT care is that it:

- ▶ Stimulates the thalamic tract
- ▶ Reduces neuro-lymphatic flow
- ▶ Increases CSF flow
- ▶ Promotes lymphatic drainage
- ▶ Reduces any nerve stasis
- ▶ Restores viscerosomatic and somatovisceral balanced function, and
- ▶ Improves circulation and stimulates normal visceral activity.

Children with nocturnal enuresis when presenting for SOT care frequently will have active kidney CMRT findings. One finding is associated with kidney ptosis, (63) which can be bilateral due to the *quadratus lumborum* myofascial tension, and is often related to increased tone in hip flexors/*psoas* muscles. In adults, this can also present as flank pain, sometimes with bladder and kidney infections. Kidney ptosis can also present as a headache at the end of the day, if someone is drinking excessive amounts of water, and even when they find themselves urinating excessively.

In the three cases presented, two of the children required repeated kidney CMRT techniques to be performed, as they were experiencing either chronic bladder or kidney infections.

### Conclusion

Nocturnal enuresis is a considerable problem for the families involved. There is not only the stigma of bedwetting, but also the associated social, psychological and physiological issues. The causes of nocturnal enuresis are many and varied, from physical problems such as a smaller bladder, to emotional issues such as stress and relationships with parents or siblings. With the three children in this case series, the same physical findings were found in all three cases, and they also each had psychosocial issues.

After their plan of care, including spinal adjustments, plus SOT techniques to balance the viscerosomatic and somatovisceral reflex activity, their nocturnal enuresis markedly reduced. Following a series of adjustments, all muscle tests, and primitive reflexes were within normal limits and their posture had improved.

While it is difficult to generalise findings of case reports to the population at large it is notable that a temporal relationship was found with the SOT/CMRT care rendered and improvement in neuromuscular function, body posture and significant reduction in nocturnal enuresis.

Rosina Walker

BChiro

Private practice of Chiropractic

Onekawa, Napier

New Zealand

[rosinawalker@gmail.com](mailto:rosinawalker@gmail.com)

---

Cite: Walker R. Sacro Occipital Technique (SOT) Chiropractic and Nocturnal Enuresis in Children: A report of three cases. Asia-Pac Chiropr J. 2023;4.1. URL [apcj.net/papers-issue-4-1/#WalkerEnuresisx3](http://apcj.net/papers-issue-4-1/#WalkerEnuresisx3)

## References

1. Gomez Rincon M, Leslie SW, Lotfollahzadeh S. Nocturnal Enuresis. 2022 Dec 3. In: StatPearls (Internet). Treasure Island (FL): StatPearls Publishing; 2023 Jan-. PMID: 31424765.
2. Graham KM, Levy JB. Enuresis. *Pediatr Rev.* 2009 May;30(5):165-72; quiz 173.
3. Thurber S. Childhood Enuresis: Current Diagnostic Formulations, Salient Findings, and Effective Treatment Modalities. *Arch Psychiatr Nurs.* 2017 Jun;31(3):319-323.
4. Dossche L, Walle JV, Van Herzeele C. The pathophysiology of monosymptomatic nocturnal enuresis with special emphasis on the circadian rhythm of renal physiology. *Eur J Pediatr.* 2016 Jun;175(6):747-54.)
5. Fagundes SN, Lebl AS, Azevedo Soster L, Sousa E Silva GJ, Silvares EF, Koch VH. Monosymptomatic nocturnal enuresis in pediatric patients: multidisciplinary assessment and effects of therapeutic intervention. *Pediatr Nephrol.* 2017 May;32(5):843-851.
6. Nevéus T. Pathogenesis of enuresis: Towards a new understanding. *Int J Urol.* 2017 Mar;24(3):174-182.
7. Butler RJ, Heron J. The prevalence of infrequent bedwetting and nocturnal enuresis in childhood. *Scand J Urol Nephrol* 2008;42(3):257-64.
8. Walker RA. Nocturnal Enuresis. *Prim Care.* 2019 Jun;46(2):243-248.
9. Paediatric Society New Zealand. Best Practice Evidence Based Guideline. Nocturnal Enuresis "Bedwetting". 2005. Available from [www.paediatrics.org.nz](http://www.paediatrics.org.nz) Accessed May 2008.
10. Kuwertz-Bröking E, von Gontard A. Clinical management of nocturnal enuresis. *Pediatr Nephrol.* 2018 Jul;33(7):1145-1154.
11. Chan IHY, Wong KKY. Common urological problems in children: primary nocturnal enuresis. *Hong Kong Med J.* 2019 Aug;25(4):305-11.
12. Bayne AP, Skoog SJ. Nocturnal enuresis: an approach to assessment and treatment. *Pediatr Rev.* 2014 Aug;35(8):327-34; quiz 335.
13. Nevéus T, Fonseca E, Franco I, Kawachi A, Kovacevic L, Nieuwhof-Leppink A, Raes A, Tekgül S, Yang SS, Rittig S. Management and treatment of nocturnal enuresis-an updated standardization document from the International Children's Continence Society. *J Pediatr Urol.* 2020 Feb;16(1):10-19.
14. Zhu W, Yue Y, Wang W, Feng J, He X, Cui L, Wan T, Wen J. Comparison of desmopressin, alarm, desmopressin plus alarm, and desmopressin plus anticholinergic agents in the management of paediatric monosymptomatic nocturnal enuresis: a network meta-analysis. *BJU Int.* 2019 Mar;123(3):388-400.
15. Caldwell PH, Sureshkumar P, Wong WC. Tricyclic and related drugs for nocturnal enuresis in children. *Cochrane Database Syst Rev.* 2016 Jan 20;2016(1):CD002117.
16. Caldwell PH, Nankivell G, Sureshkumar P. Simple behavioural interventions for nocturnal enuresis in children. *Cochrane Database Syst Rev.* 2013 Jul 19;(7):CD003637.
17. Kamperis K. Nocturnal enuresis in children: The role of arginine-vasopressin. *Handb Clin Neurol.* 2021;181:289-297.
18. Su MS, Xu L, Pan WF, Li CC. Current perspectives on the correlation of nocturnal enuresis with obstructive sleep apnea in children. *World J Pediatr.* 2019 Apr;15(2):109-116.
19. de Medeiros Alves AC, de Medeiros Padilha H, de Andrade Barbalho AL, Gonçalves Tomaz AF, Gomes Pereira HS, Rabelo Caldas SGF. Influence of rapid maxillary expansion on nocturnal enuresis in children. *Angle Orthod.* 2021 Sep 1;91(5):680-691.
20. Fernandes AER, Roveda JRC, Fernandes CR, Silva DF, de Oliveira Guimarães IC, Lima EM, de Carvalho Mrad FC, de Almeida Vasconcelos MM. Relationship between nocturnal enuresis and sleep in children and adolescents. *Pediatr Nephrol.* 2023 May;38(5):1427-1438.
21. Fernandes AER, Roveda JRC, Fernandes CR, Silva DF, de Oliveira Guimarães IC, Lima EM, de Carvalho Mrad FC, de Almeida Vasconcelos MM. Relationship between nocturnal enuresis and sleep in children and adolescents. *Pediatr Nephrol.* 2023 May;38(5):1427-1438.)
22. de Sena Oliveira AC, Athanasio BDS, Mrad FCC, Vasconcelos MMA, Albuquerque MR, Miranda DM, Simões E Silva AC. Attention deficit and hyperactivity disorder and nocturnal enuresis co-occurrence in the pediatric population: a systematic review and meta-analysis. *Pediatr Nephrol.* 2021 Nov;36(11):3547-3559.
23. Phung P, Kelsberg G, Safranek S. Clinical Inquiry: Does primary nocturnal enuresis affect children's self-esteem? *J Fam Pract.* 2015 Apr;64(4):250-9.)
24. Van Herzeele C, De Bruyne P, De Bruyne E, Walle JV. Challenging factors for enuresis treatment: Psychological problems and non-adherence. *J Pediatr Urol.* 2015 Dec;11(6):308-13.

25. Egan R, McCormick CL. Resolution of enuresis in a 10-year-old male following subluxation-based chiropractic care: A case study (case report). *J Pediatr Matern & Fam Health - Chiropr*: Aug 2022: 66-74.
26. Steinberg B, Postlethwaite R, Mclvor C. Decrease in allergies, nocturnal enuresis and sleep problems in a 3-year-old under chiropractic care: A case report. *Asia-Pac Chiropr J*. 2022;2.5.
27. Blonigen A, Postlethwaite R, Mclvor C. Resolution of nocturnal enuresis in 9 year-old male under chiropractic care: A Case Report. *Asia-Pac Chiropr J*. 2021;2.6.
28. Treahy-Geofreda T, Lanoue B, Postlethwaite R, Mclvor C. Improved Physical Adaptability in a 3.5-Year-Old Female with an Abnormal Birth History: A case report. *Asia-Pac Chiropr J*. 2022;2.6.
29. Herring R, Wright D. Resolution of nocturnal enuresis, constipation, headaches, allergies and cold hands in a 6-year-old male following chiropractic for vertebral subluxation: Case study and review of the literature (case report; review). *J Pediatr Matern & Fam Health - Chiropr*: Aug 2020(2020:): 26-33.
30. Defrancq K. Primary monosymptomatic nocturnal enuresis: can chiropractors handle this? An evidence-based case report. *J Clin Chiropr Pediatr*: Jun 2020(19:1): 1629-1632.
31. Mason TL, Alcantara Joel. Resolution of headaches and enuresis in a child undergoing chiropractic care to reduce vertebral subluxations: A case report and review of literature. *J Pediatr Matern & Fam Health - Chiropr*: May 2019: 41-45.
32. St-Jean A. Chiropractic care of a 10-year-old female with primary nocturnal enuresis: A case report. *J Clin Chiropr Pediatr*: Nov 2018;17(3):1490-1495.
33. Shtulman I, Miller H, Alcantara Joel. Resolution of nocturnal enuresis, dysponesis and dysautonomia in a 17-year-old male following chiropractic care for vertebral subluxation (case report). *J Pediatr Matern & Fam Health - Chiropr*: Dec 2018: Online access only 155-160.
34. Rollette D, LaMarca C. Resolution of enuresis, constipation and dysautonomia in a 9-year-old child following chiropractic care for management of vertebral subluxation: A case study and review of literature (case report, review). *J Pediatr Matern & Fam Health - Chiropr*: Jun 2018: Online access only 57-67.
35. Marko S, Marko J. Resolution of otitis media and nocturnal enuresis in a 12-year-old patient following chiropractic care to reduce vertebral subluxations: A case study and selected review of the literature (case report; review). *J Pediatr Matern & Fam Health - Chiropr*: Apr 2018(2018:): Online access only 13-25.
36. Shtulman I, Cunningham MA. Resolution of constipation and nocturnal enuresis in a 10-year-old female following adjustment of vertebral subluxations: A case study (case report). *J Pediatr Matern & Fam Health - Chiropr*: Spring 2016(2016:2): Online access only 61-67.
37. Instebø E, Lystad RP. Chiropractic Care of an 8-Year-Old Girl With Nonorganic, Primary Nocturnal Enuresis: A Case Report. *J Chiropr Med*. 2016 Mar;15(1):47-52.
38. Alcantara Joel, Neally R. Resolution of chronic nocturnal enuresis in children with Asperger's syndrome following subluxation based chiropractic care: A case series (case report). *J Pediatr Matern & Fam Health - Chiropr*: Fall 2015;4: Online access only 131-139
39. Hafer C. Resolution of nocturnal enuresis following adjustment of vertebral subluxations: A case report. *J Pediatr Matern & Fam Health - Chiropr*: Winter 2015(2015:1): Online access only 5-8.
40. Singh KK, Alcantara J, Holt K. Improvement in a pediatric patient with autistic spectrum disorder (ASD) following a trial of chiropractic care: A case report. *J Clin Chiropr Pediatr*: Nov 2014;14(3): Online access only 1183-1186.
41. Luscombe S, Holmes S. Resolution of nocturnal enuresis in a 10-year old child following chiropractic care to reduce vertebral subluxation: A case report (case report). *J Pediatr Matern & Fam Health - Chiropr*: Summer 2014(2014:3): Online access only 55-59.
42. Milano K. Resolution of childhood enuresis and neck pain in a 10 year old male: A case report (case report). *J Pediatr Matern & Fam Health - Chiropr*: Fall 2013(2013:4): Online access only 90-94.
43. Noriega A, Chung J, Brown J. Improvement in a 6 year-old child with Autistic Spectrum Disorder and nocturnal enuresis under upper cervical chiropractic care (case report). *J Upper Cervical Chiropr Res*: Winter 2012(2012:1): 1-8.
44. Weisberg JE. Resolution of nocturnal enuresis and vertebral subluxation in a pediatric patient undergoing chiropractic care: A case report and review of the literature (case report; review). *J Pediatr Matern & Fam Health - Chiropr*: Fall 2010(2010:4): Online access only 143-149.
45. van Poecke AJ, Cunliffe C. Chiropractic treatment for primary nocturnal enuresis: a case series of 33 consecutive patients. *J Manipulative Physiol Ther*. 2009 Oct;32(8):675-81.
46. Glazener CM, Evans JH, Cheuk DK. Complementary and miscellaneous interventions for nocturnal enuresis in children. *Cochrane Database of Systematic Reviews*. 2005: CD005230.



47. [https://wikichiro.org/en/index.php/Sacro\\_Occipital\\_Technique](https://wikichiro.org/en/index.php/Sacro_Occipital_Technique) (Last accessed 23 May, 2023)
48. Getzoff H. Sacro-Occipital Technique categories: A systems method of chiropractic. *Chiropr Tech*: May 1999(11:2):62-65.
49. Getzoff H. A critical approach for learning the Operating Principles of Sacro Occipital Technique (SOT) Chiropractic. *Asia-Pac Chiropr J*. 2023;3.4. URL [apcj.net/Papers-Issue-3-4/#GetzoffSOTPrinciples](http://apcj.net/Papers-Issue-3-4/#GetzoffSOTPrinciples)
50. [https://wikichiro.org/en/index.php/Chiropractic\\_Manipulative\\_Reflex\\_Technique](https://wikichiro.org/en/index.php/Chiropractic_Manipulative_Reflex_Technique) (Last accessed 23 May, 2023)
51. Blum CL. Chiropractic Manipulative Reflex Technique (CMRT): A position statement. *Sacro Occipital Technique Organization – USA*. (SOT Research Section of SOTO-USA Website) 2008: 1-3.
52. Rosen MG, Blum C. Chiropractic Care of paediatric non-musculoskeletal conditions: A retrospective patient survey. *Asia-Pac Chiropr J*. 2021;1.3:Online only.
53. Postles A, Haavik Taylor H. Changes in asthma symptoms and bedwetting in a four year old child receiving chiropractic care: A case report. *Chiropr J Aust*. 2010 Mar;40(1):34-36.
54. Zafeiriou DI. Primitive reflexes and postural reactions in the neurodevelopmental examination. *Pediatr Neurol*. 2004 Jul;31(1):1-8.
55. Benner C, Blum C. Chiropractic Manipulative Reflex Technique and Acupuncture in Treatment of Dysmenorrhea (Oligomenorrhea): A Case Report. *J Chiropr Educ* (2012) 26 (1): 49-50s.
56. Shirazi D, Del Torto A, Blum C. Dental chiropractic non-surgical co-treatment of a 48-year-old male patient with a deviated septum, headaches, and TMJ dysfunction a case report. *Chiropractic Journal of Australia*. 2021; 48(1):1-9.
57. Blum CL. The resolution of chronic colitis with chiropractic care leading to increased fertility. *J Vert Sublux Res (JVSR)*. 2003;Aug 31:5.
58. Getzoff, H (May 2012). A study of the nature of SOT occipital line fibers: A retrospective case series of 65 patients. 4th Annual Sacro Occipital Technique Research Conference Proceedings: Atlanta, GA. *Sacro Occipital Technique Organization – USA*: Sparta, NC: 42-47.
59. Thompson J, Bockhold H. Sacro Occipital Technique: Occipital Fiber Technique on a Canine. *J Chiropr Educ* (2012) 26 (1): 116–135.
60. Thompson JE, Bockhold H, Blum CL. Sacro Occipital Technique: Palpating Occipital Fibers on Animals – A Pilot Study. 11th International Research and Philosophy Symposium (IRAPS), Sherman College of Chiropractic, Spartanburg, SC, October 16-19, 2014. *Ann Vert Sublux Res*. 2015 Spring;2:Online access only 48-98.
61. Mootz R, Jameson S, Menke M, Inter and Intra-Rater Reliability of Occipital Fiber Palpation. *Proceedings of the Fifth Annual Conservative Health Science Research Conference*. Oct 1986: 37-9.
62. Ferreira AA, Trindade FP, Depintor JDP, Benedicto CC. Analysis of the relationship of the procedure occipital fibers of Sacro Occipital Technique with vertebral and visceral injuries. (Portuguese) *Brazil J Chiropr*. 2012;3(1):23-33.
63. Blum CL. Chiropractic Manipulative Reflex Technique (CMRT) Manual: Based on the Writings of Dr. M. B. DeJarnette. *Sacro Occipital Technique Organization – USA*: Sparta, North Carolina, USA. 2007:viii-ix, 13-14.

## About the Chiropractor



Dr. Rosina Walker is a graduate of the New Zealand College of Chiropractic and is the President of *Sacro Occipital Technique Organisation - New Zealand (SOTO-NZ)*. As President, Dr. Walker helps organise and teach sacro occipital technique (SOT) seminars around the New Zealand. Dr. Walker loves seeing people from across the age spectrum, from newborn babies, toddlers, teens, mums and dads and the more mature age group. Dr. Walker loves using the SOT and the changes it makes to people's bodies and health. She has primarily used this technique for the last ten years. However, she also uses a variety of other techniques depending on what our practice members require.